

# MYCOTOXIN LESIONS IN THE SLAUGHTERHOUSE—PIGS



**SPECIAL NUTRIENTS**

THE MYCOTOXINS SPECIALIST

[www.mycotoxin.com](http://www.mycotoxin.com)

## MYCOTOXINS LESIONS IN PIGS IN SLAUGHTERHOUSE

The main problem with mycotoxicosis in pigs is that in most cases this intoxication occurs gradually. Pigs will ingest sublethal amounts of the toxin for a prolonged period of time, affecting their health status. The manifestation is a growth reduction and poor performance. The analysis of mycotoxins in feed previously consumed by the animals is normally the method used to establish a relationship between the lesions observed in the slaughterhouses and mycotoxins. A problem with this method is that the contaminated feed could have been consumed in the early stages of production and is no longer available for analysis. Another problem is the possibility that the feed analyzed is not the one causing the clinical symptoms.

This guide will help to associate lesions detected at the slaughterhouse with the mycotoxins identified in feed analysis. In addition, this brochure will help to evaluate the effectiveness of the preventative measures adopted to control the contamination of grains, feed and silos.

A key factor in the control of mycotoxicosis is establishing a good diagnosis capable of showing both the presence and the severity of the lesions. The examination of gross lesions is routinely performed in animals at the slaughterhouse.

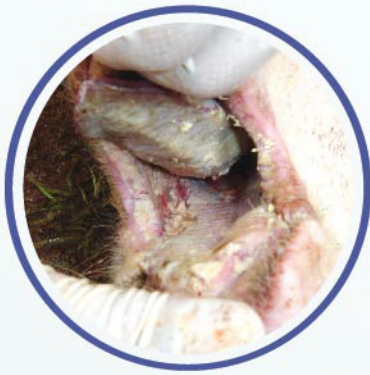Table 1 shows the organs and lesions that can be caused by mycotoxins. The routine review of organs can be adjusted to each company's schedule to be performed monthly or twice a year. A minimum of 45 animals must be examined per session. Tissue samples of lesions should be also taken for histopathology. The spleen is an important organ of the immune system so it should always be included in the evaluation.

Table 1. Evaluation of lesions caused by mycotoxins in different organs.

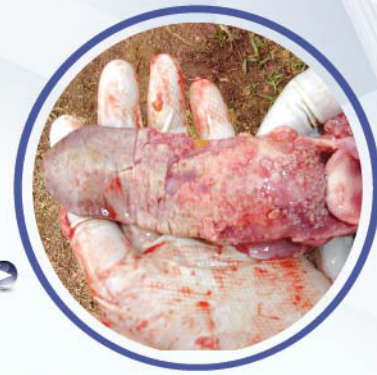EVALUATION OF LESION		
ORGAN		CAUSE
Oral Cavity	Ulcers, necrosis.	T2
Stomach	Ulcer, epithelial desquamation, damaged pars esophagi, and hemorrhages.	
Esophagus	Ulcers, epithelial desquamation, and hemorrhages.	
Intestines	Hemorrhages.	
Spleens	Size reduction, whitish coloration, and low organ activity (low immunity).	
Lung	Interlobular and mediastinal edema. Hypertrophy.	Fumonisin
Liver	Acute cases: Hepathosis (degenerative process), hepatohegaly, and friable. Chronic cases: Hard to the touch, cirrhosis, fibrous tissue (whitish spots). Pale or grayish color.	Aflatoxin
Stomach	Ulcer.	
Spleen	Size reduction, grayish or whitish color, and low activity (low immunity).	
Esophagus	Epithelial desquamation, and ulcers.	Vomitoxin
Stomach	Epithelial desquamation, lymphoid reaction, damaged pars esophagi, and ulcers.	
Skin	Ear necrosis, hoof necrosis, and tortuous blood vessels.	Ergotoxins
Kidney	Nephrosis, hypertrophy, whitish spots in surface. Cysts.	Ochratoxin
Spleen	Size reduction, and grayish or whitish coloration (low immunity).	
Uterus	Hydrometra, hypertrophy.	Zearalenone
Ovary	Cysts.	
Vulva	Vulvovaginitis.	

## ORAL CAVITY, ESOPHAGUS, STOMACH, AND INTESTINAL LESIONS

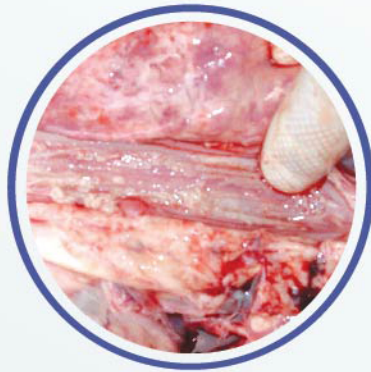They are usually observed as irritations with a reddish color or whitish plaques. Localized in the tongue and palate, they can reach the esophagus, stomach and intestines depending on the severity. In severe cases there is epithelial necrosis and desquamation. This lesion, caused by T2 toxin is seldom observed because animals normally die as a result of the severity of the injuries.



◀ Whitish plaques



Epithelium detachment ▶



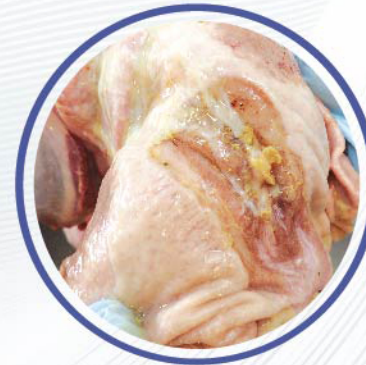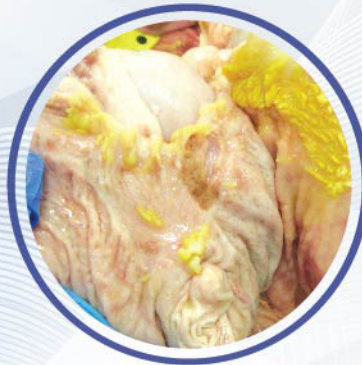
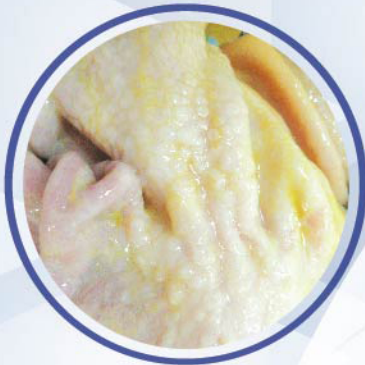Esophagus. Irritation and whitish plaques



Intestinal hemorrhages

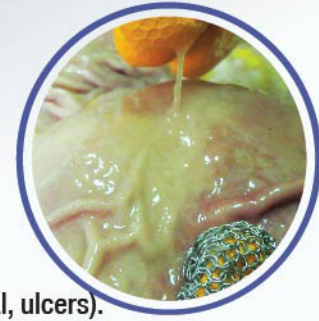## STOMACH LESIONS

The lesions vary from irritation, desquamation of the epithelium, mucous exudate, lymphoid reaction, metaplasia, parakeratosis, ulcers, and damage in pars esophageal.



The causes can include the following etiologies:

- Aflatoxins (ulcers).
- Vitamin E deficiency (ulcers).
- Prolonged fasting (irritation, ulcers).
- Vomitoxin (lymphoid reaction, metaplasia).
- Inflammatory processes (presence of mucous exudate).
- T-2 toxin (irritation, lymphoid reaction, metaplasia, damage in pars esophageal, ulcers).
- Variations in granulometry (lymphoid reaction, metaplasia, irritation, ulcers, damage in esophageal pars).

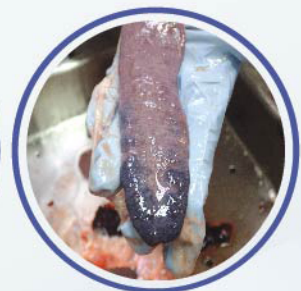
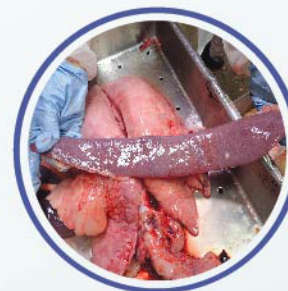
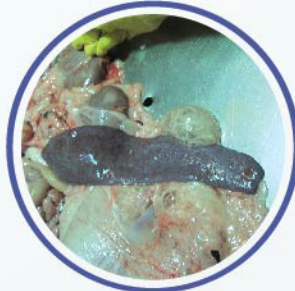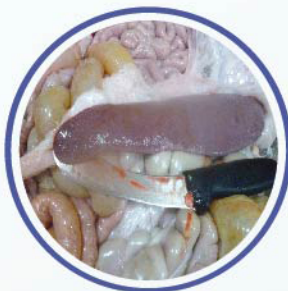## **SPLEEN LESIONS**

The spleen is an important organ that reflects the immune status of the animal. Erythrocytes and defense cells are produced in the spleen. Atrophy is an indication of low immunity and an inactive spleen, sometimes also with grey or whitish coloration. An enlarged spleen suggests an active septicemic process.

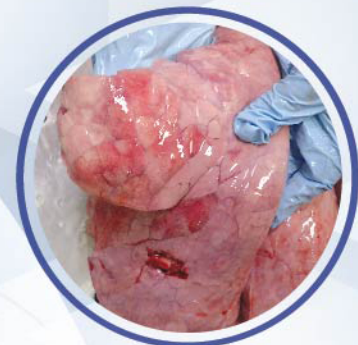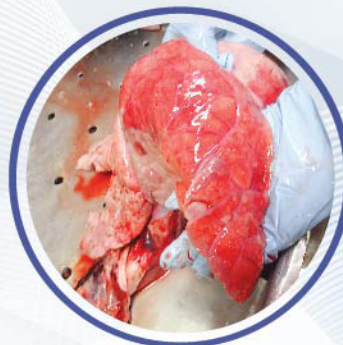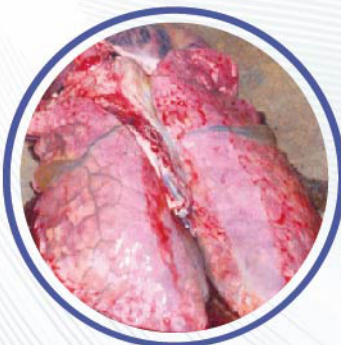- Splens diminished in size, in cases of poisoning with T-2 toxin, aflatoxins or ochratoxins.

- Enlarged (splenomegaly) in infectious septicemic processes.



## **LUNG LESIONS**

The principal lesion is the presence of interstitial or interlobular edema, which is related to intoxication with fumonisin. Porcine circovirus 2 also causes this type of edema, but interstitial pneumonia is also present. Histopathology will allow a definitive diagnosis.

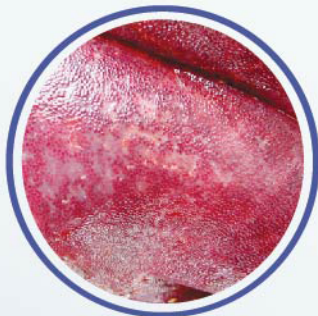


## LIVER LESIONS

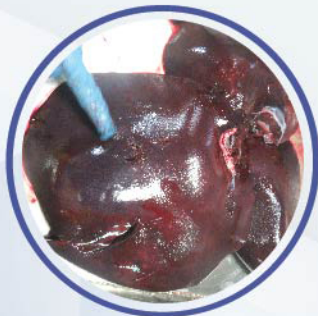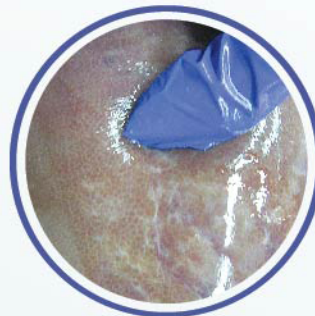The lesions present vary from paleness, jaundice with abnormalities in biliary pigments, irregular whitish spots, and hard to the touch consistency (fibrosis, cirrhosis). Also, severe congestion, reddish color, and friable to the touch (acute hepatothosis) are present. Histopathology will help to establish a definitive diagnosis, since aflatoxins cause proliferation of the bile ducts.

### Causes:

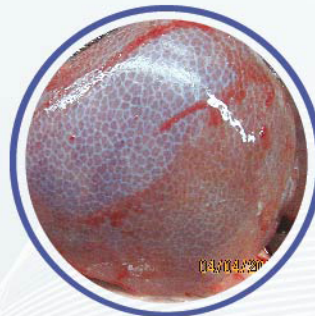
- ▶ Aflatoxins. In an acute process, reddish and friable livers will be observed. Chronic process cause pale and fibrous livers, hard to the touch, and whitish spots.
- ▶ Chronic intoxication. Pale and fibrous livers, hard to the touch with whitish spots are present.
- ▶ Vitamin E deficiency. Dietary hepatothosis, friable and diffuse reddish spots are present in a septicemic process.
- ▶ Bacterial infections. Depending on the type of bacteria present, there may be abscesses. The organ is whitish and friable, if it is an acute septicemic process and hard to the touch with fibrosis when the process is chronic.
- ▶ Viral infections. In acute processes the organ is reddish and friable. In chronic cases the liver is hard to the touch, and shows cirrhosis.
- ▶ Miscellaneous intoxications. Severe hepatothosis and degenerative changes are detected in the hepatocytes.



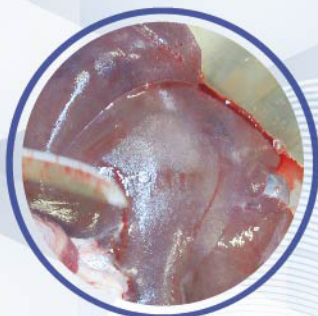Chronic process: fibrosis, cirrhosis, and diffuse whitish spots



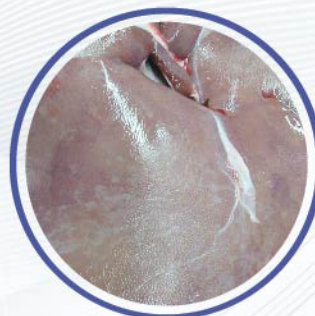
Acute process: congested, friable



Fibrosis



Pale, cirrhotic, diffuse whitish spots, hard to the touch



## KIDNEY LESIONS

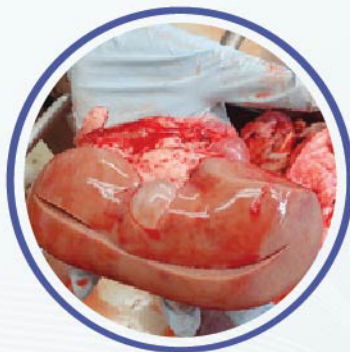Widespread whitish spots, paleness, cysts of different sizes and shapes, enlargement, and nephrosis can be present. Histopathology will help us obtain an accurate diagnosis.

Causes:

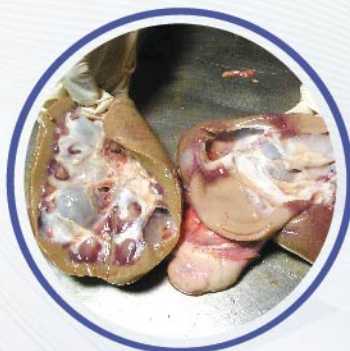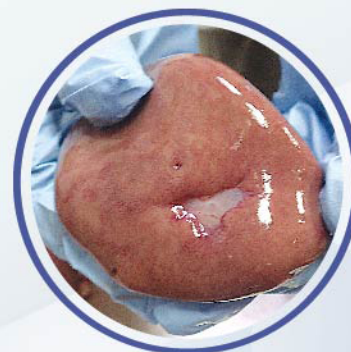- ▶ Ochratoxin. Whitish coloration, swelling, enlargement, icteric appearance, and the presence of cysts.
- ▶ Leptospirosis. Widely spread whitish spots.
- ▶ Porcine circovirus. Enlarged and friable.
- ▶ Hepatitis. Generates yellowish color in the kidneys due to variation in the concentration of biliary pigments.
- ▶ Congenital cysts. Embryonic problems that tend to disappear shortly after birth.



White spots,  
increase in size

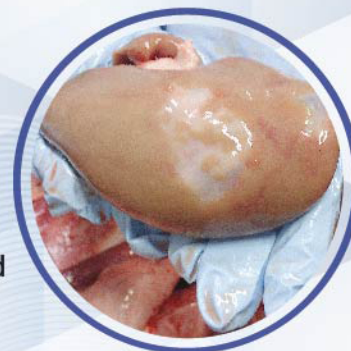

Cysts of different sizes and  
shapes



Cysts

Cysts and repaired  
tissue

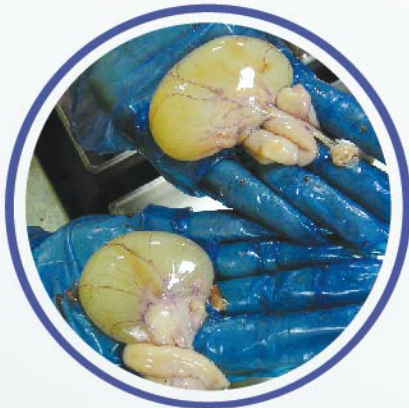

## LESIONS IN THE REPRODUCTIVE TRACT

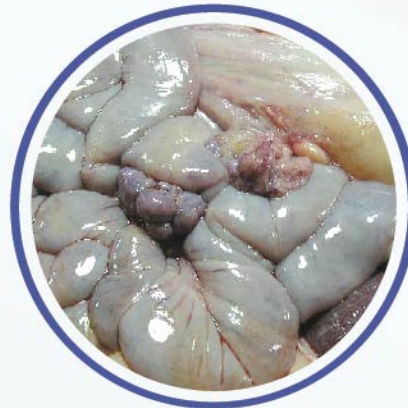Hydrometra, cysts in ovaries, and hypertrophy. In order to obtain a final diagnosis, other organs must be examined to rule out a possible vitamin E deficiency that may influence fertility and cause a hormonal imbalance.

Causes:

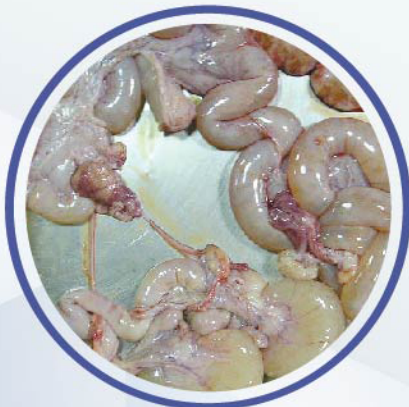- ▶ Vitamin E deficiency. Infertility problems.
- ▶ Zearalenone. Hydrometra, enlargement of the uterus and presence of cysts in the ovaries. Hormonal imbalance showing ovaries with presence of corpora lutea, cysts, hemorrhagic or atresic bodies in great quantity.



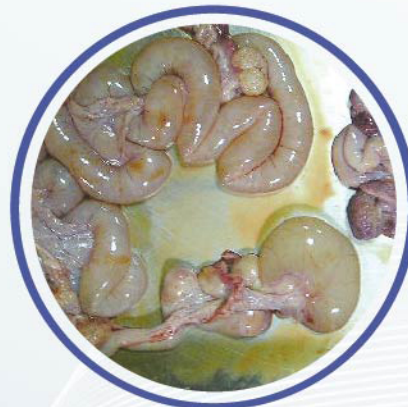Cysts



Hydrometra and corpora lutea




Enlargement of the uterus



Hydrometra

In conclusion, mycotoxins are products of fungal metabolism that may be contaminating the grains without the pig producer having knowledge. The rapid recognition of the lesions and clinical signs suggestive of mycotoxins intoxication, can represent a big difference in terms of the final effect that this type of intoxication can have on the performance and profitability. A recognized problem of contaminated rations can be more easily controlled before it causes irreversible damage to the swine population. The support of diagnostic techniques, such as slaughterhouse monitoring, should be used whenever possible.

## Does your anti-mycotoxin additive meet the basic TOP and FACTS?

Target  Organ Protection			
Mycotoxin	Organ	MYCOAD	MYCOAD AZ
Aflatoxin	Liver	YES	NO
Ochratoxin	Kidney	YES	NO
T-2 Toxin	Oral lesion	YES	YES
Fumonisin	Heart / Lung / Liver	YES	YES*
Zearalenone	Reproductive	N/A	YES
DON	Liver	N/A	YES
Facts		MYCOAD	MYCOAD AZ
<i>In vivo</i> dosage with TOP results		2.5 Kg / MT	1 kg / MT
Recommended commercial dosage		2.5 kg / MT	1 kg / MT
The clay is <b>always obtained</b> from the <b>same mine</b>		YES	YES
Approved in <b>Texas, USA</b> , against Aflatoxin		YES	N/A
Approved in the <b>European Union</b> against Aflatoxin. Regulation #1831 / 2003 (1m 588)		YES	N/A
<b>ENDOTOXIN</b> adsorption		N/A	YES
Efficacy approved by <b>LAMIC</b> and other institutions against the following number of mycotoxins		4	4
Efficacy approved by <b>LAMIC</b> and other institutions in different types of animals		6	5
Nutrient absorption		NO	NO
<i>In vitro</i> efficacy test every:		100 MT	18 MT

\* Test performed with 4 Kg / MT with 30,000 ppb of fumonisin  
N/A= not applicable

MYCOAD = Cobind, Toxfree Standard  
MYCOAD AZ = Cobind AZ, Toxfree

Copyright April 2018. Special Nutrients. All Rights Reserved.