EVALUATION OF THE EFFICACY OF A COMMERCIAL PURIFIED PHYLOSILICATE TO REDUCE THE TOXICITY OF T-2 TOXIN IN BROILER CHICKS.

A. Casarin[1], M. Forat[1], E. Soto[2], and D. Zaviezo*[3]

[1]Instituto Internacional Investigacion Animal, Queretaro, Mexico, [2]Avimex, Mexico, [3]Special Nutrients, Miami, FL USA.

INTRODUCTION

IMycotoxins cause a wide variety of adverse clinical signs, depending on the nature and concentration of toxins in the diets, animal species, age; and nutritional and health status at the time of exposure to contaminated feed. The presence of mycotoxins in poultry feeds is of concern because it has resulted in economic losses due to poor health and reduced performance. (7)

T-2 toxin (T-2) is a naturally occurring mycotoxin from the group of the trichothecenes, produced by Fusarium spp. mainly before harvesting. Trichothecene toxins have been most often characterized by oral lesions and reduced growth in chickens, as well as the inhibition of protein synthesis, responsible for the negative effects on rapidly dividing cells such as those of the oral cavity, gastrointestinal tract, and lymphoid tissues (10, 14). In addition, Burditt et al. (3) found that T-2 toxin produced a dose related feed refusal, suggesting that it may have been due to the irritative properties of trichothecenes.

Practical methods to detoxify mycotoxins contaminated grain or feed on a large scale and in a cost-effective manner are not currently available. At present, one of the most practical approaches consist on using adsorbent materials in the diet to reduce the absorption of mycotoxins from the gastrointestinal tract. Hydrated sodium calcium aluminum silicates (HSCAS) represent an important group of products that have been used with success worldwide against aflatoxin and ochratoxin. (2, 4, 9, 10) Myco-Ad has been the only HSCAS that effectively prevented the toxic effect of 1.0 or 1.25 ppm of T-2 when added at 2.5 kg per metric ton (MT) of broiler feed. (5)

The objectives of this research were to determine the efficacy of a low inclusion purified phylosilicate, Myco-Ad® A-Z, to ameliorate the toxic effects of T-2 in the broiler diet and to demonstrate that Myco-Ad® A-Z would not negatively affect broiler performance.

MATERIALS AND METHODS

This experiment was conducted at the Instituto Internacional de Investigacion Animal, Queretaro, Mexico. Feed was experimentally contaminated with synthetic T-2 toxin from Sigma Chemical Company, St. Louis, MO, USA. The product used was a commercial modified phylosilicate, Myco-Ad® A-Z, produced in Texas (Special Nutrients, Miami, FL, USA)

A total of 32 five-day-old Ross male broiler chicks from a commercial hatchery were used in this experiment for 33 days. Chicks were individually caged and reared under uniform management conditions, with feed and water provided ad libitum. Birds were fed a basal sorghum-soybean meal mash diets that met or exceeded the levels of nutrients recommended by the NRC (11). The chicks were randomly distributed into four treatments with 8 replications each. Dietary treatments were as follows: 1) control diet; 2) control diet plus 0.1% Myco-Ad A-Z; 3) control diet with the addition of 1.25 mg of T-2 / kg of feed; and 4) control diet with 1.25 mg T-2 / kg of feed plus 0.1% Myco-Ad A-Z. Chickens were weighed individually, total feed consumption recorded, and scored for oral lesions at 38 days of age. At the end of the experiment all birds were sacrificed to carry out histopathological analysis of bursa, thymus, tongue and gizzard. Bone ash, bone calcium and bone phosphorus were measured in all broilers from treatment 1 and 2, following the A.O.A.C. method of analysis (1)

Oral lesion score consisted of a four point scoring system ranging from 0 to 3, including lesions detected at several sites within the mouth, mainly on the upper and lower mandibles, the corners of the mouth, and on the tongue. A lesion score 0 indicates no visible lesions; score 1 was seen as one mild mouth lesion; score 2 was seen as up to two moderate lesions; and a lesion scored as 3 indicated more than two severe lesions.

Data were evaluated with ANOVA for a complete randomized design, using the general linear models procedure of SAS software; SAS Institute (13). When the ANOVA showed significance, Duncan's significant-difference test was applied. Statistical significance was accepted at $P \leq 0.05$.

RESULTS

The effects of dietary treatments on chick performance from day 5 to 38 as well as oral lesions at 38 days of age are presented in Figures 1, 2, 3, and 4. Consumption of T-2 contaminated feed resulted in significant reduction in body weight gain (18%), poorer feed efficiency (14%), and increased amount and severity of oral lesions. Supplementation of 0.1% Myco-Ad A-Z to the diet contaminated with 1.25 ppm T-2 significantly improved gain, feed efficiency and reduced the incidence of oral lesions. Body weight gain, feed consumption, efficiency of feed utilization, oral lesion scores and bone mineralization (Table1) were not significantly influenced by the adsorbent in the absence of added T-2.

The report from the histopathological analyses indicated that at 38 days 80% of the birds showed moderate microscopic damage of the bursa and gizzard; and about 50% of them presented severe lesions in thymus and tongue when fed a diet with 1.25 ppm T-2. Addition of 0.1% Myco-Ad A-Z to the T-2 contaminated diet markedly reduced the degree and number of lesions in those organs, to a level comparable to the one reported in the control diet. (Table 2)

DISCUSION

The addition of 1 kg of Myco-Ad A-Z per MT of feed significantly diminished the adverse effects of T-2 in broiler chicks. This is the first report showing the in vivo effectiveness of an adsorbent against T-2 at such a low inclusion level. The protective action of this modified phylosilicate appears to involve sequestration of T-2 so that it is not available for absorption by the chicks, as suggested by Phillips et al. (12) for aflatoxin.

In spite of the effectiveness of Myco-Ad A-Z in preventing the decreased broiler performance and organs damage produced by the addition of T-2, mild oral lesions were observed in some chickens fed the adsorbent in the contaminated diet. Probably, they are a consequence of the direct T-2 caustic effect in the mouth (8), where the lack of appropriate conditions, especially liquid medium and low pH, prevent the action of the adsorbent.

Results obtained in these experiment demonstrate that 1.25 mg of T-2 per kg of feed can produce the typical signs of an acute T-2 toxicosis in broilers, similar to those reported in the literature (6, 8) when using levels of T-2 greater than 2 mg/kg. According to Hoerr (8), it is the severe ulcerative stomatitis produced by T-2 that leads to decreased feed intake, reduced gain and decreased feed efficiency.

EFFECTS OF MYCO-AD A-Z ON BODY WEIGHT GAIN, FEED INTAKE, FEED CONVERSION AND ORAL LESION SCORE OF 38 DAY-OLD BROILERS EXPOSED TO TEST DIETS FOR 33 DAYS

Figure 1. Effect of Myco-Ad A-Z on body weight gain of 38 day-old broilers exposed to test diets for 33 days.

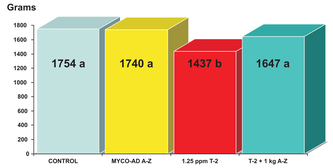

Figure 2. Effect of Myco-Ad A-Z on feed intake of 38 day-old broilers exposed to test diets for 33 days.

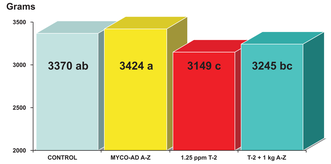

Figure 3. Effect of Myco-Ad A-Z on feed conversion of 38 day-old broilers exposed to test diets for 33 days.

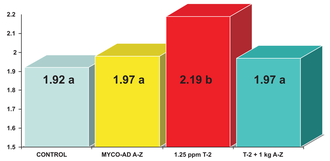

Figure 4. Effect of Myco-Ad A-Z on oral lesion score of 38 day-old broilers exposed to test diets for 33 days.

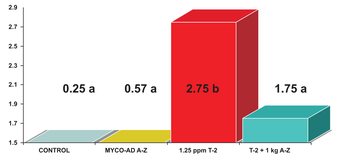

a, b, c Values within columns with different superscripts are significantly different (P<0.05)

Table 1 Effect of Myco-Ad A-Z on bone mineralization of 38 day-old broilers

Treatment	Bone Ash %	Bone Calcium %	Bone Phosphorus %
Control	45.95[a]	23.87[a]	8.71[a]
Control + 0.1% Myco-Ad A-Z	44.20[a]	25.11[a]	8.66[a]

a Values within columns with different superscripts are significantly different (P<0.05)

Table 2 Microscopic organ lesions of 38 day-old broilers exposed to test diets for 33 days

Treatment	Tongue[1]	Gizzard[2]	Thymus[3]	Bursa[4]
Control	25% Mild	40% Mild	40% Mild	40% Mild
Control + 0.1% Myco-Ad A-Z	None	40% Mild	40% Mild	None
Control + 1.25 ppm T-2	25% Mild 25% Moderate 50% Severe	20% Mild 80% Moderate	25% Mild 30% Moderate 45% Severe	80% Moderate
Control + T-2 + Myco-Ad A-Z	25% Mild	40% Mild	40% Mild	40% Mild

1 Tongue: ulcerative glositis. 3 Thymus: focal hemorrhage. 2 Gizzard: erosive ventriculitis. 4 Bursa: follicular atrophy.

CONCLUSIONS

1. **The addition of 1.0 kg of Myco-Ad A-Z per MT of feed was effective in preventing the deleterious effects caused by T-2 in broiler chickens.**
2. **The addition of 1.0 kg of Myco-Ad A-Z per MT of feed did not show any statistical difference in performance and bone mineralization of broilers compared to those from the control diet, demonstrating its lack of nutrientsabsorption.**

REFERENCES

1. Association of Official Agricultural Chemist, 2000. Official Methods of Analysis, 17th Edition. Washington, D.C.

2. Bailey, R.H., L.F. Kubena, R.B. Harvey, S.A. Buckley, and G.E. Rottinghaus. 1998. Efficacy of various inorganic sorbents to reduce the toxicity of aflatoxin and T-2 toxin in broiler chickens. Poultry Sci. 77:1623-1630.

3. Burditt, S.J., W.M. Hagler, Jr., and P.B. Hamilton. 1983. Survey of molds and mycotoxins for their ability to cause feed refusal in chickens. Poultry Sci. 62:2187-2191.

4. Casarin, A., M. Forat, E. Soto, M. Contreras, and D. Zaviezo. 2005. Evaluation of the efficacy of a commercial hydrated sodium calcium aluminosilicate to reduce the toxicity of aflatoxin and ochratoxin in broiler chicks. Poultry Sci. 84 Suppl.1 pp. 131.

5. Casarin, A., M. Forat, E. Soto, B. Fazekas, J. Tanyi, and D. Zaviezo. 2005. Evaluation of the efficacy of a commercial hydrated sodium calcium aluminosilicate to reduce the toxicity of T-2 toxin in broiler chicks. Poultry Sci. 84 Suppl.1 pp. 132.

6. Chi, M.S., C.J. Mirocha, H.J. Kurtz, G. Weaver, F. Bates, and W. Shimoda. 1977. Subacute toxicity of T-2 toxin in broiler chicks. Poultry Sci. 56:309-313

7. Dmello, J., and A.M.C. Macdonald, 1977. Mycotoxins. Animal Feed Science Technology. 69:155-166.

8. Hoerr, F.J., 2003. Mycotoxicoses. Pages 1103-1132 in Diseases of Poultry. Ed by I. Saif. 11th ed. Iowa State Press. Ames, Iowa.

9. Kubena, L.F., R.B. Harvey, W.E. Huff, D.E Corrier, T.D. Phillips, and G.E. Rottinghaus. 1990. Efficacy of a hydrated sodium calcium aluminosilicate to reduce the toxicity of aflatoxin and T-2 toxin. Poultry Sci. 69:1078-1086.

10. Leeson, S., G.J. Diaz, and J.D. Summers, 1995. Trichothecenes. Pages 190-226 in Poultry Metabolic Disorders and Mycotoxins. University Books, Guelph, Canada.

11. National Research Council. 1994. Nutrient Requirement for Poultry. 9th rev. ed. National Academy Press. Washington, D.C.

12. Phillips, T.D., B.A. Clement, L.F. Kubena, and R.B. Harvey. 1990. Detection and detoxification of aflatoxins: prevention of aflatoxicosis and aflatoxin residues with hydrated sodium calcium aluminosilicate. Vet. Human Toxicol. 32:15-19.

13. SAS Institute. 1987. SAS/STAT Guide for Personal Computers. Version 6.02 Edition. SAS Institute Inc., Cary, North Carolina.

14. Ueno, Y., 1991. Biochemical mode of action of mycotoxins. Pages 438-455 in Mycotoxins in Animal Feeds. J.E. Smith and R.S. Henderson, Eds. CRC Press, Boca Raton, Florida.

ABSTRACT

The use of 2.5 kg/mt of a commercial HSCAS (Myco-Ad) have been previously demonstrated to effectively prevent the toxic effect of 1.25 ppm T-2 toxin (T-2) in broilers. An experiment was conducted to study the efficacy of a very low inclusion commercial purified phylosilicate (Myco-Ad A-Z) in preventing the deleterious effects of T-2 in broiler chicks. Thirty two 5-day-old Ross male broiler chicks individually caged were randomly distributed into four dietary treatments with 8 replications each. Birds were fed a basal sorghum-soybean meal mash diet containing or exceeding NRC recommended nutrients levels. The feed was experimentally contaminated with synthetic T-2 from Sigma Chemical Company, USA. Treatments were: (1) control diet; (2) control + 1.0 kg/mt Myco-Ad A-Z; (3) control + 1.25 ppm T-2; and (4) control + 1.25 ppm T-2 + 1.0 kg/mt Myco-Ad A-Z. Results at 38 days of age indicated that broilers fed 1.25 ppm T-2 contaminated diet presented significant lower body weight, poorer feed conversion, and severe macroscopic oral lesions than chicks fed the control diet. The addition of Myco-Ad A-Z to the contaminated diet resulted in statistically significant heavier (1772 v 1563 g) and more efficient (1.97 v 2.19) broilers, with statistically reduced gross oral lesions and substantial reduction in microscopic organs lesions (tongue, gizzard, thymus, and bursa) than those fed 1.25 ppm T-2. The addition of 1.0 kg/mt of Myco-Ad A-Z to chick diets did not show any statistical difference in performance and bone mineralization compared to the control diet, demonstrating its lack of interference with nutrients absorption. These results indicated that Myco-Ad A-Z at 1.0 kg/mt was effective in preventing the toxic effects of T-2 in broilers chicks.

Key Words: Myco-Ad A-Z, T-2 toxin